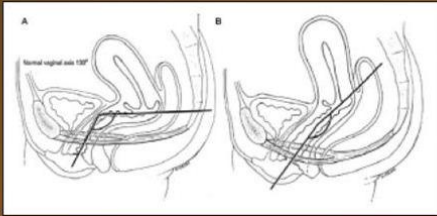
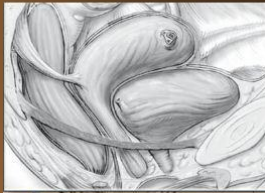

# GIẢI PHẪU ỨNG DỤNG

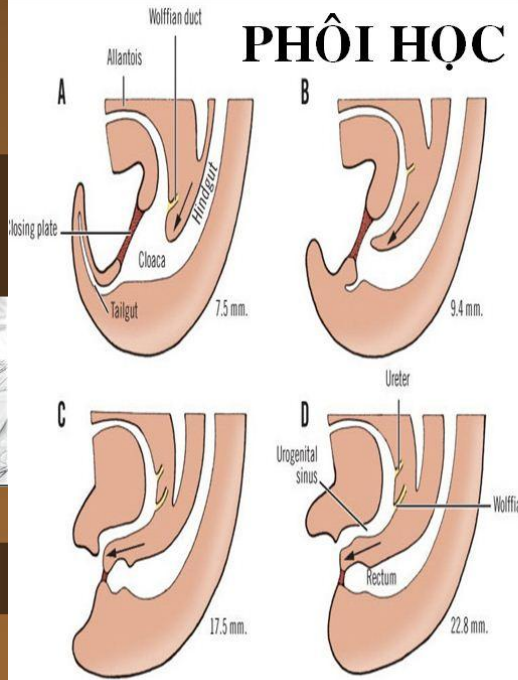
## SÀN CHẬU NỮ

- ❖ GIẢI PHẪU HỌC TĨNH (MÔ TẢ)
- ❖ GIẢI PHẪU HỌC ĐỘNG (CHỨC NĂNG)
- ❖ GIẢI PHẪU ỨNG DỤNG (NGOẠI KHOA)

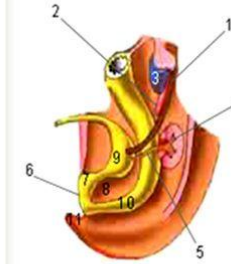


Nguyễn Trung Vinh

## PHÔI HỌC

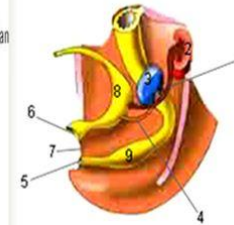


Formation of the urogenital sinus



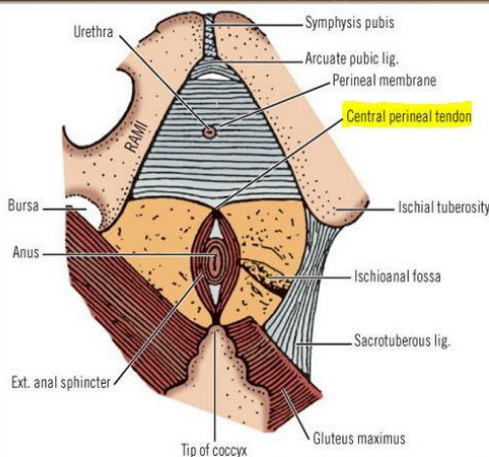
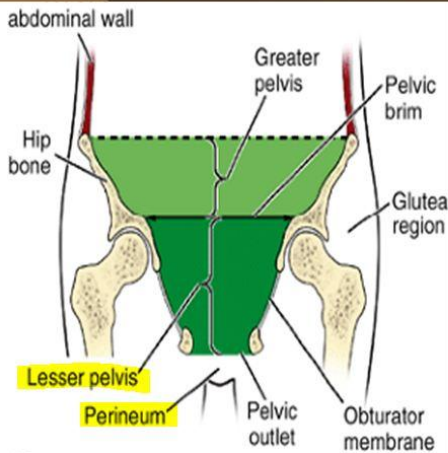
1. Mesonephric duct
2. Mesonephros
3. Gonad
4. Metanephros
5. Ureter
6. Cloacal membrane
7. Cloaca
8. Urorectal septum
9. Urogenital sinus
10. Anorectal canal
11. Tail

Formation of the urogenital sinus



1. Ureter
2. Metanephros
3. Gonad
4. Mesonephric duct
5. Anal membrane
6. Urogenital membrane
7. Perineal body
8. Bladder
9. Rectum

## GIẢI PHẪU HỌC: GIỚI HẠN



## SÀN CHẬU TRƯỚC

### Skin

### Subcutaneous tissue

- Camper's fascia
- Colles fascia
- Superficial space
- Clitoris and its crura
- Ischiocavernosus muscle
- Vestibular bulb
- Bulbocavernosus muscle
- Greater vestibular gland
- Superficial transverse perineal muscle
- Deep space-perineal membrane
- Compressor urethrae
- Urethrovaginal sphincter

## LỚP DƯỚI DA

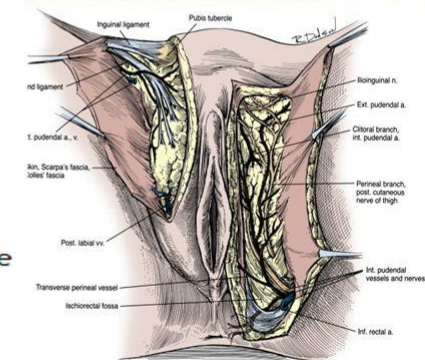


Figure 2-47 Arteries and nerves of the female perineum. (From Doherty MS. Clinical anatomy of the pelvis. In Copeland L. Gynecology. Philadelphia, WB Saunders, 1993, p 51.)

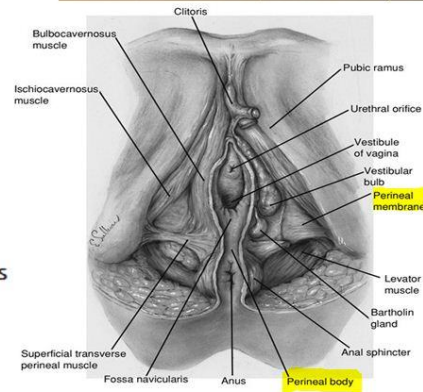
## PERINEOLOGY PELVI-PERINEOLOGY

ANT. PERINEAL COMPARTMENT  
POST. PERINEAL COMPARTMENT

# SÀN CHẬU TRƯỚC

Skin  
 Subcutaneous tissue  
 Camper's fascia  
 Colles fascia  
**Superficial space**  
 Clitoris and its crura  
 Ischiocavernosus muscle  
 Vestibular bulb  
 Bulbocavernosus muscle  
 Greater vestibular gland  
 Superficial transverse perineal mus  
 Deep space-perineal membrane  
 Compressor urethrae  
 Urethrovaginal sphincter

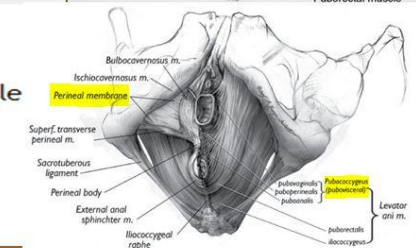
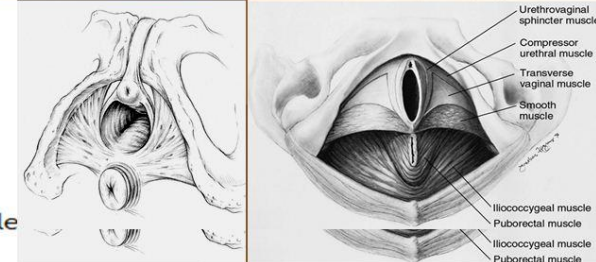
## LỚP NÔNG



# SÀN CHẬU TRƯỚC

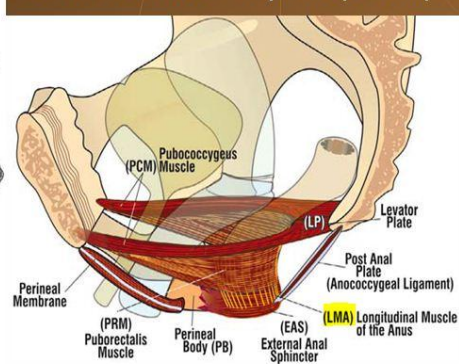
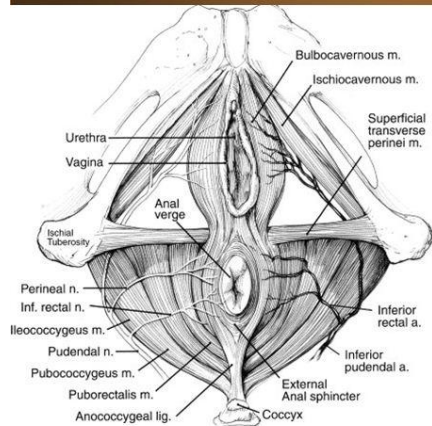
## LỚP SÂU

Skin  
 Subcutaneous tissue  
 Camper's fascia  
 Colles fascia  
**Superficial space**  
 Clitoris and its crura  
 Ischiocavernosus muscle  
 Vestibular bulb  
 Bulbocavernosus muscle  
 Greater vestibular gland  
 Superficial transverse perineal muscle  
**Deep space**-perineal membrane  
 Compressor urethrae  
 Urethrovaginal sphincter

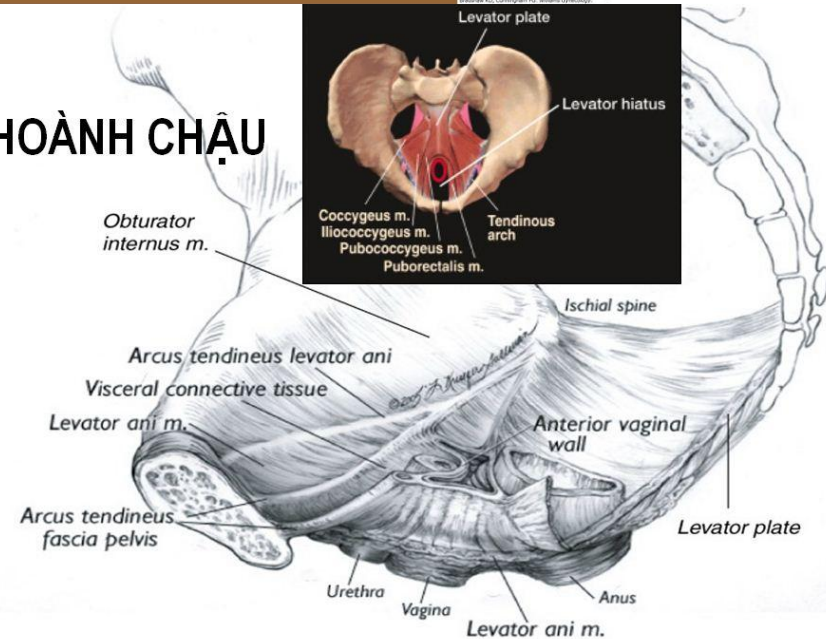


# HOÀNH NIỆU DỤC CƠ & MÀNG SÀN CHẬU

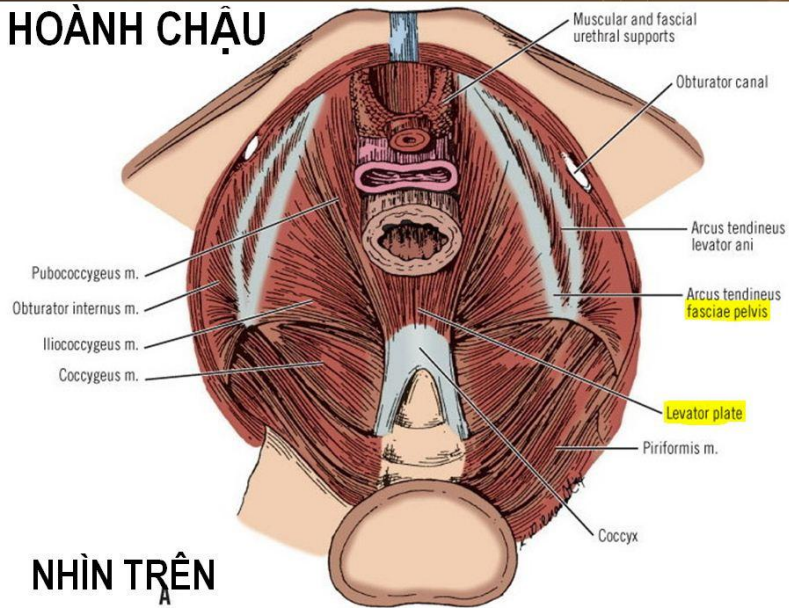
## HOÀNH CHẬU CƠ NÂNG HM & MẠC NỘI CHẬU



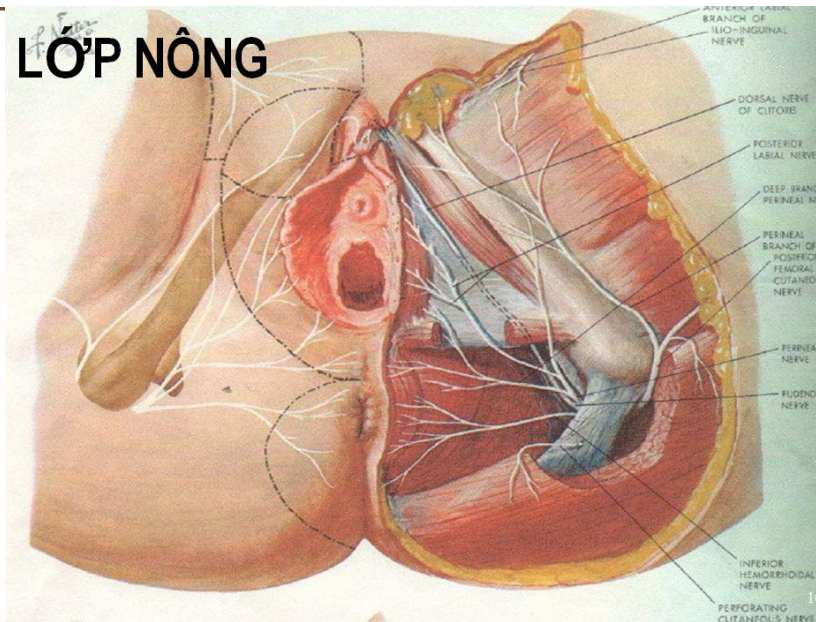
# HOÀNH CHẬU



# HOÀNH CHẬU

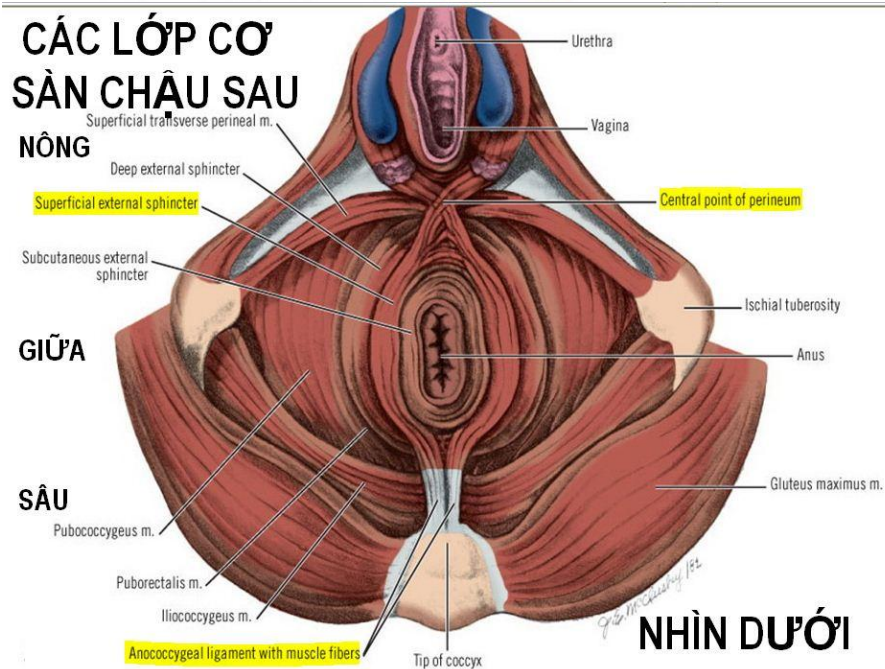


# LỚP NÔNG

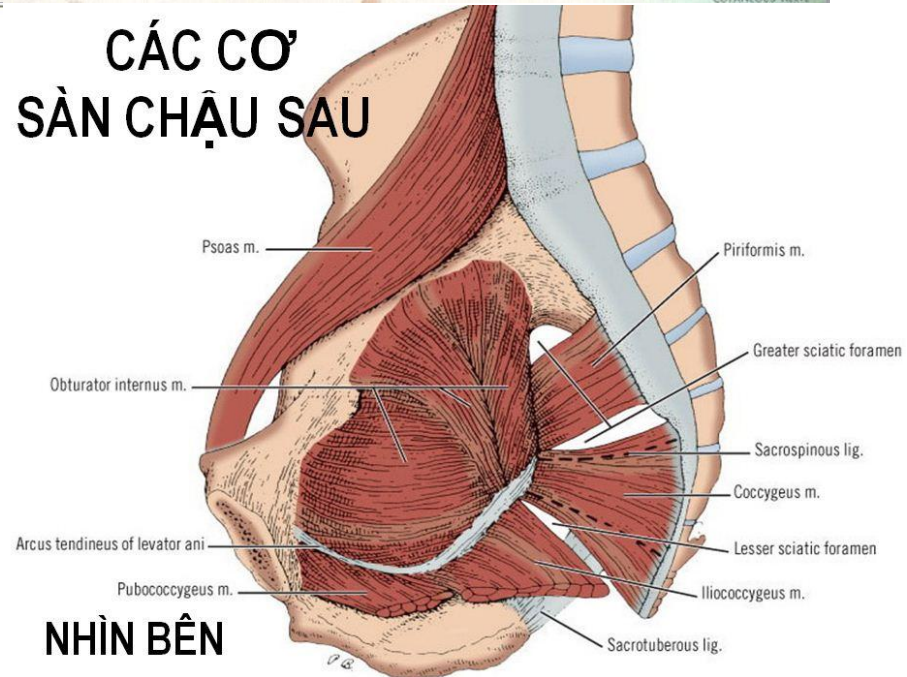


# NHÌN TRÊN

## CÁC LỚP CƠ SÀN CHẬU SAU NÔNG

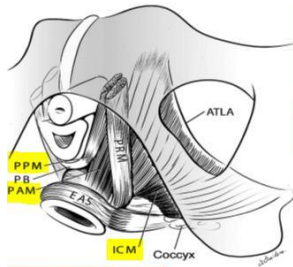


## CÁC CƠ SÀN CHẬU SAU

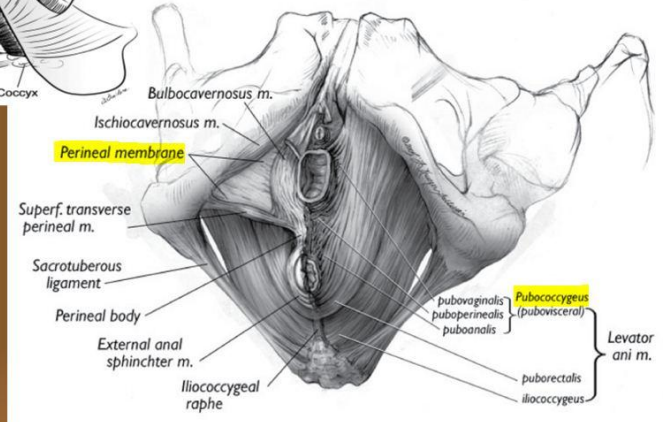


# NHÌN DƯỚI

# NHÌN BÊN

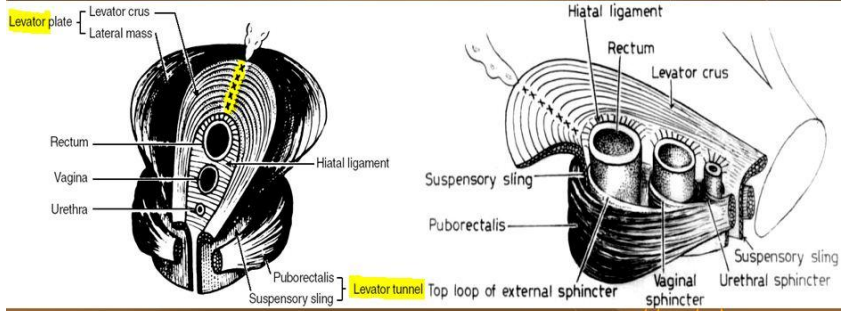


# PUBOCOCCYGEUS M. CƠ MŨ CỤT

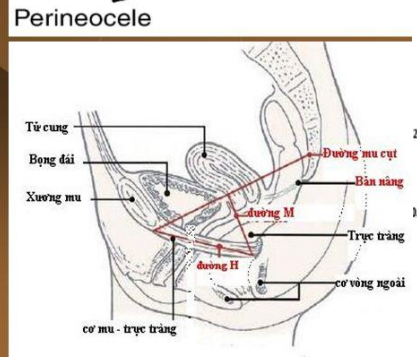
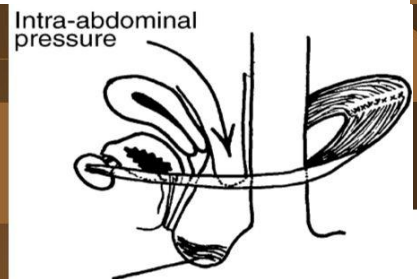
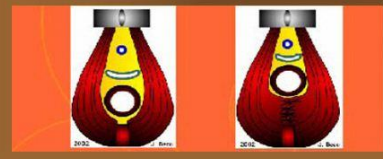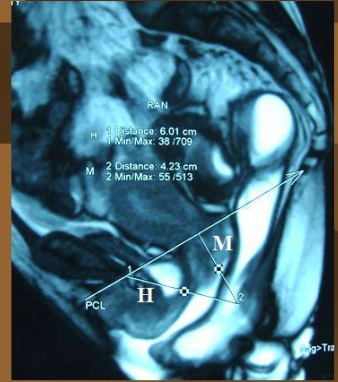


Source: Schorge JO, Schaffer JI, Halvorson LM, Hoffman BL, Bradshaw KD, Cunningham FG - Williams Gynecology

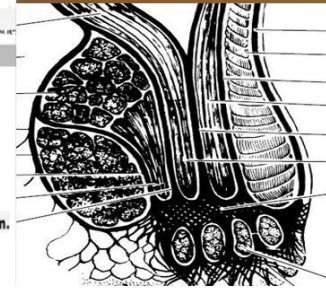
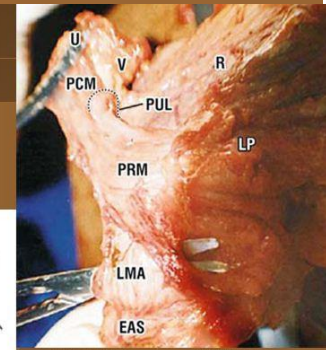
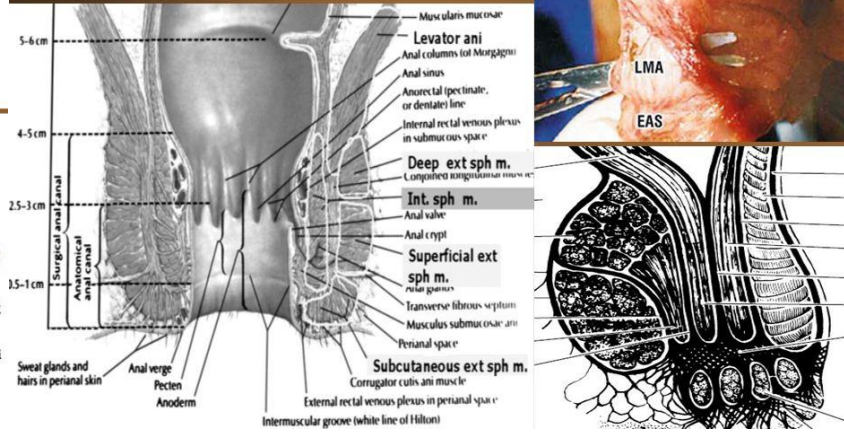
# BẢN & ỐNG CƠ NÂNG HẬU MÔN



# Sa Bản cơ nâng HM

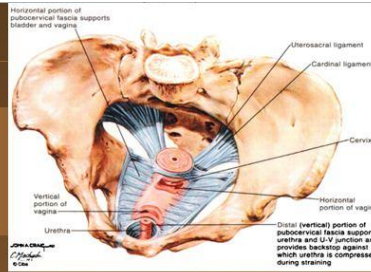


# LỚP CƠ DỌC HẬU MÔN HỆ CƠ THẮT (TRONG, NGOÀI)

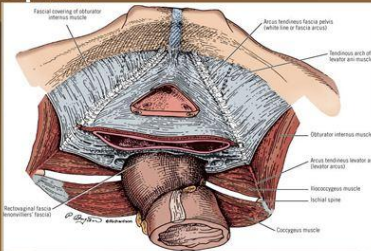


# THREE SUPPORT LEVELS

- Level- I (Tent pole): Uterine - Cervix**
- Uterosacral Cardinal ligaments
  - Cervical ring

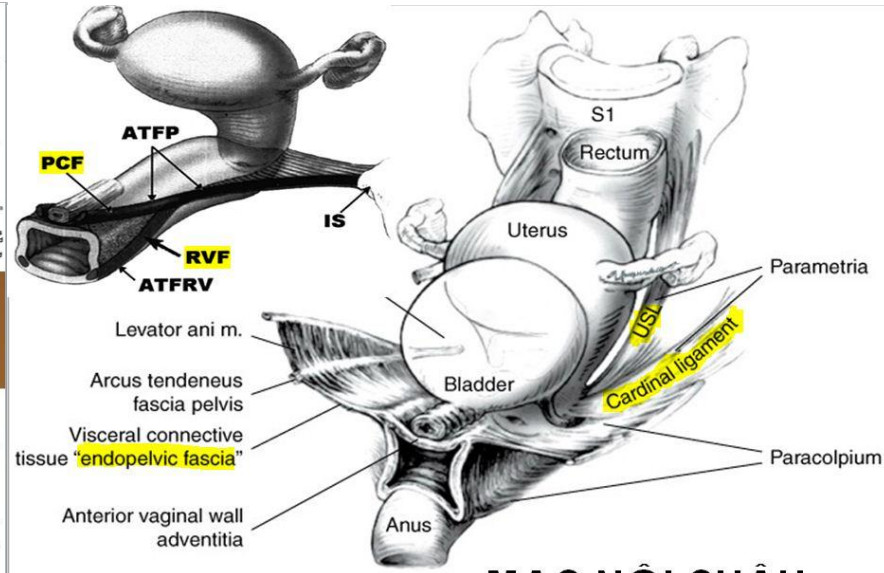


- Level- II (Tent sides): Horizontal Vagina**
- Arcus Tendineus Pelvis Fasiae - ATPF
  - Pubocervical fascia, Rectovaginal septum



- Level- III (Tent pegs): Verti. Vagina**
- Urethra & U-V Junction
  - Perineal body (posterior)

DeLancey JOL, Clinical Obstet and Gynecol (1993) 36: 4,897-909

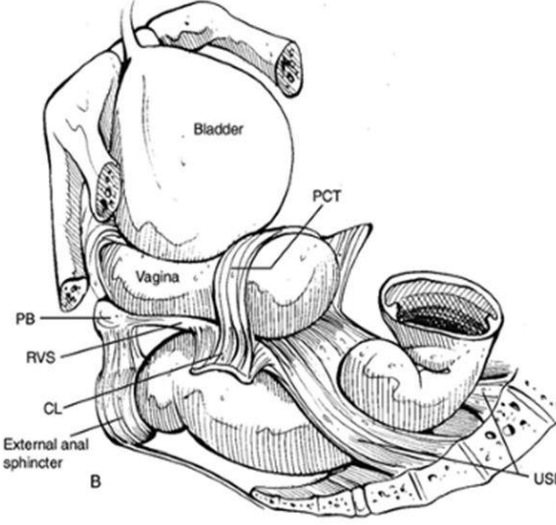
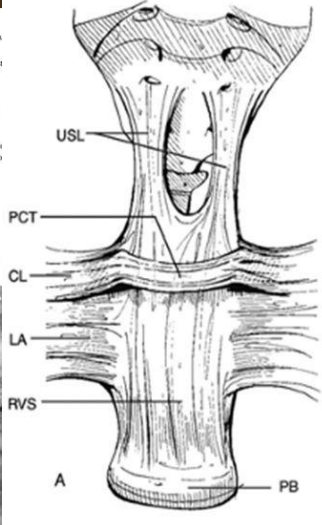
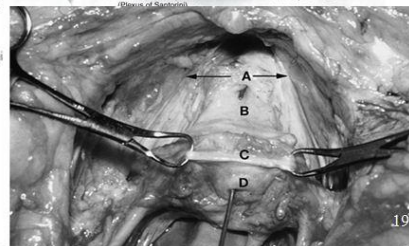
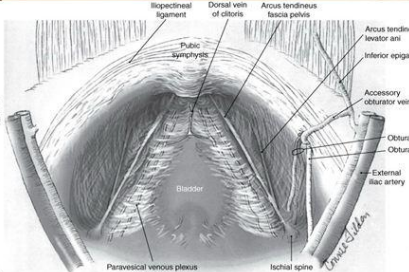
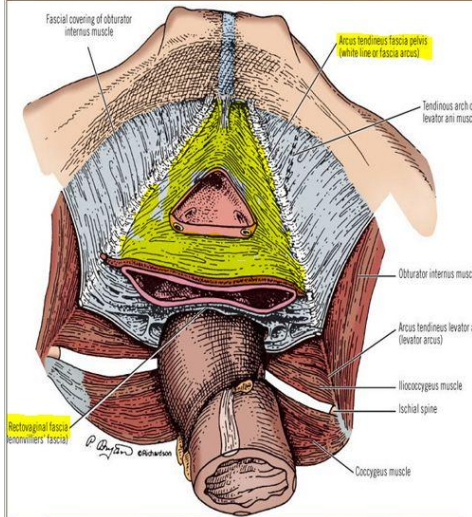


Source: Schorge JO, Schaffer JI, Halvorson LM, Hoffman BL, Bradshaw KD, Cunningham FG: Williams Gynecology; <http://www.accessmedicine.com>  
Copyright © The McGraw-Hill Companies, Inc. All rights reserved.  
Pelvic viscera and their support.

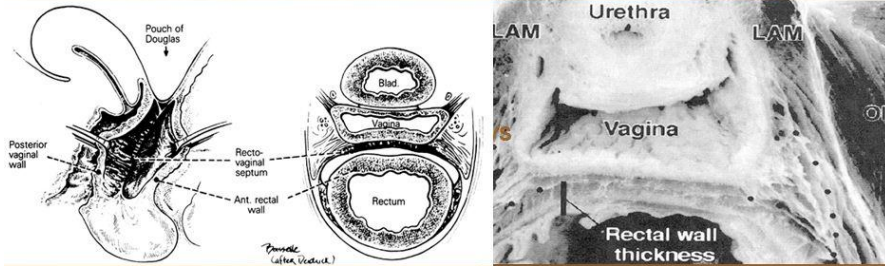
## MẠC NỘI CHẬU

# MẠC MU CỖ - PUBOCERVICAL FASCIA

# Posterior Vaginal Compartment Rectovaginal septum



## VÁCH TRỰC TRÀNG ÂM ĐẠO ?

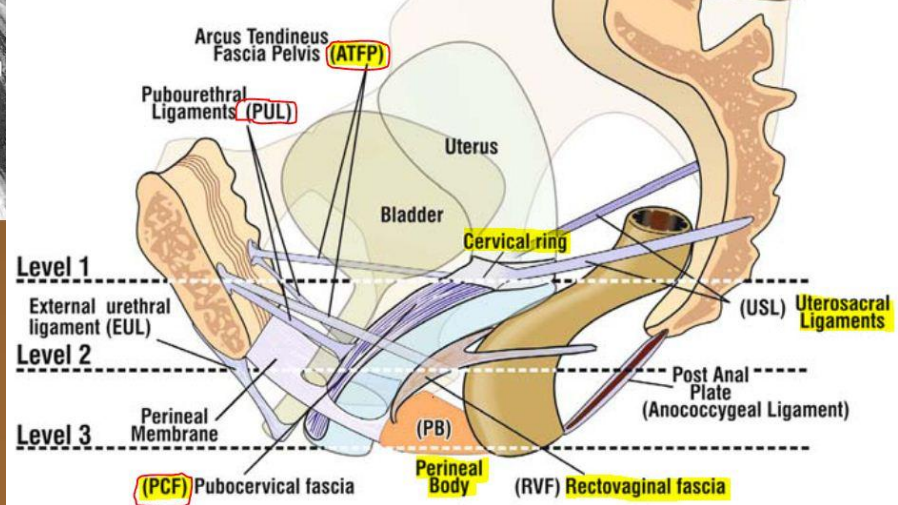


	Group 1 (n = 20)	Group 2 (n = 20)	Group 3 (n = 20)	P value
Mean ± SD (mm)	3.896 ± 0.3617	4.6575 ± 0.3052	10.058 ± 0.4534	P < 0.01

Jin Liu, Li-Dong Zhai, Yun-Sheng Li. Measuring the space between vagina and rectum as it relates to rectocele. *World J Gastroenterol* 2009 June 23; 15(24): 3051-3054

21

## 3 LỚP MẠC VÀ DÂY CHẰNG 2 TRỤC TREO GIỮ TRƯỚC - SAU



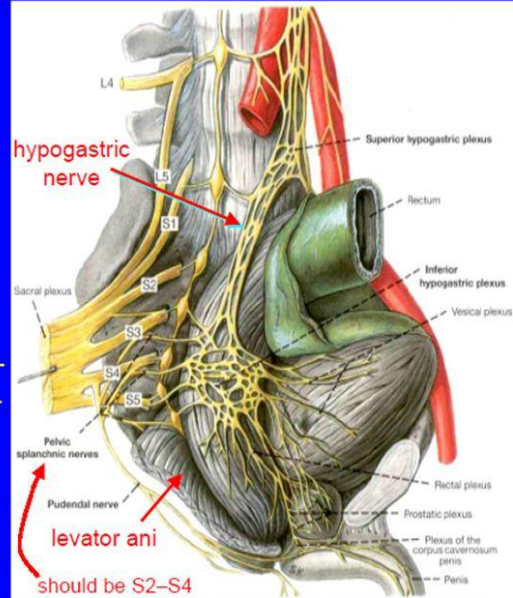
## Nerve Supply to the Anorectal Region

### Somatic innervation

- Pudendal nerve (S2–S4)
  - Inferior rectal n.: sensory & motor to muscles & mucosa below dentate line
  - Perineal n.: sensory & motor to perineal region

### Autonomic innervation

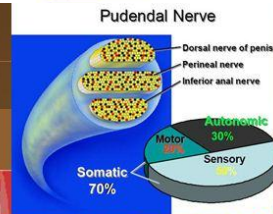
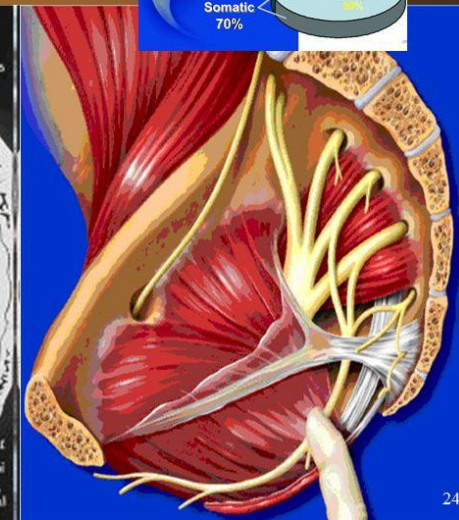
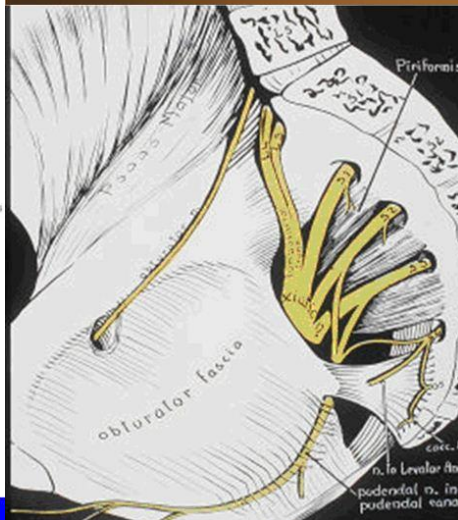- Sympathetics from thoracolumbar segments via sup. hypogastric plexus & hypogastric nn.
- Parasympathetics from S2–S4 (nervi erigentes)
- Unite in inf. hypogastric plexus
- Distributed to pelvic viscera & sexual organs



From Clemente (1997)

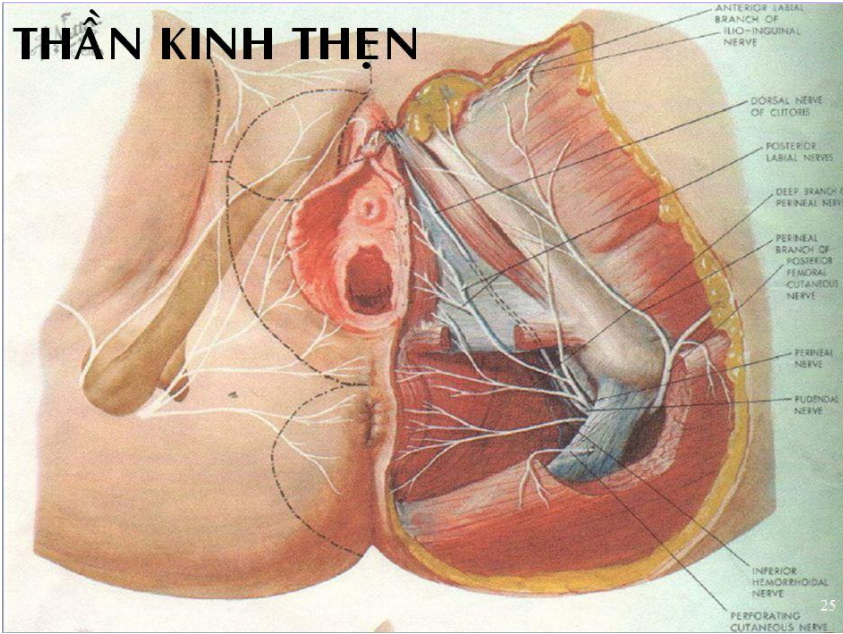
20

## THẦN KINH THẬN

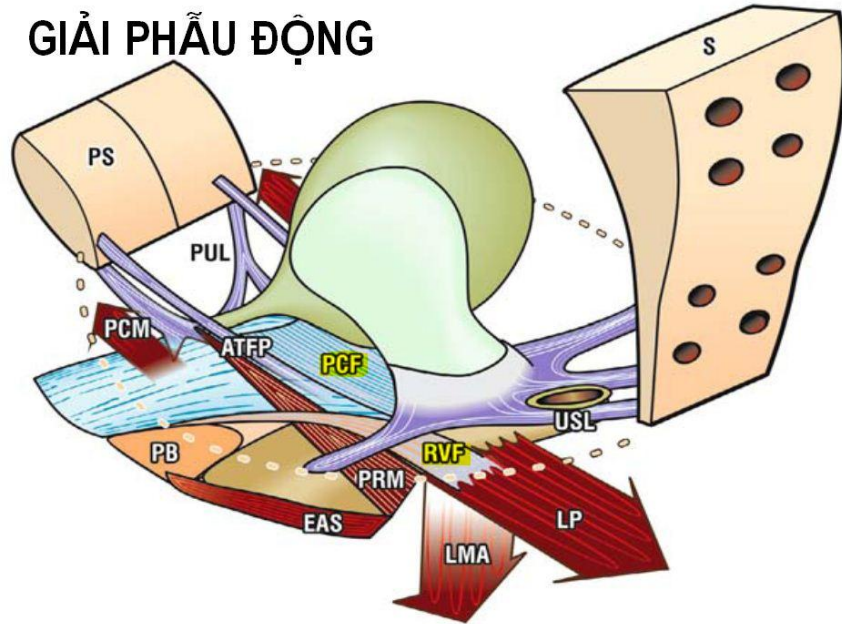


24

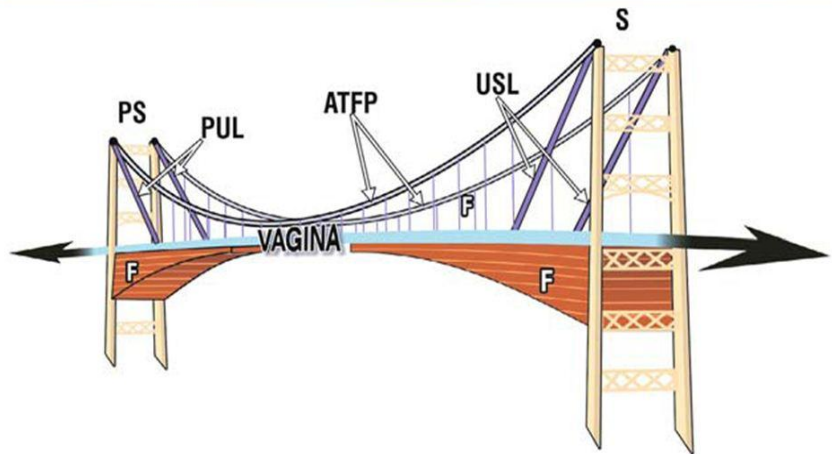
# THẦN KINH THẬN



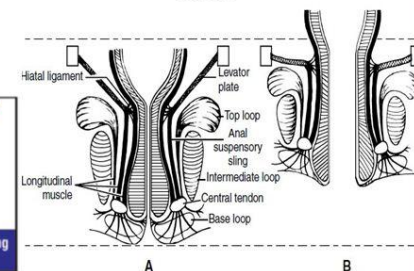
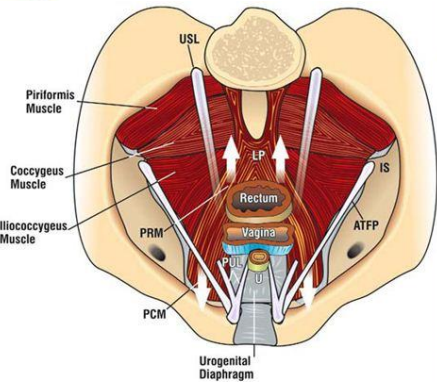
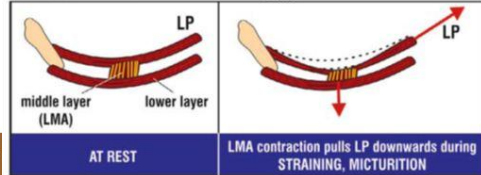
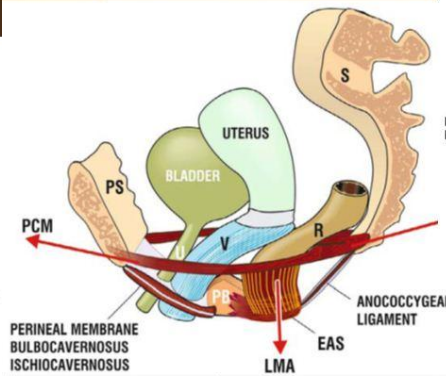
# GIẢI PHẪU ĐỘNG



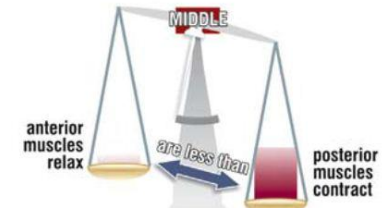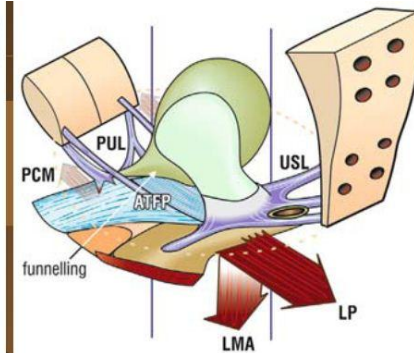
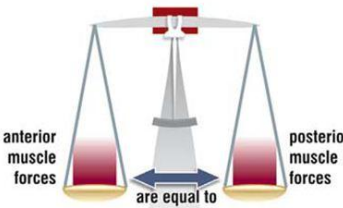
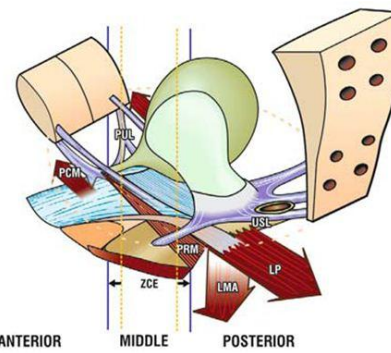
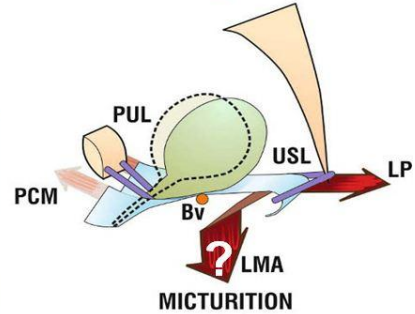
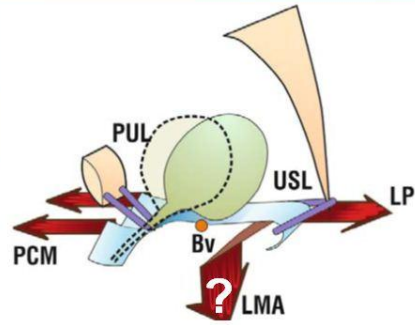
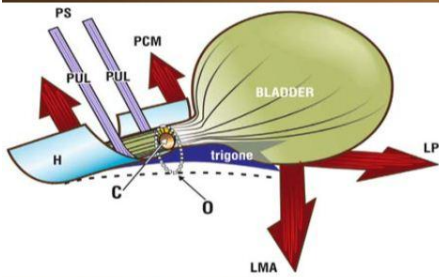
# MÔ HÌNH CẤU TRÚC NÂNG ĐỖ SÀN CHẬU



# CƠ CHẾ ĐẠI TIỆN

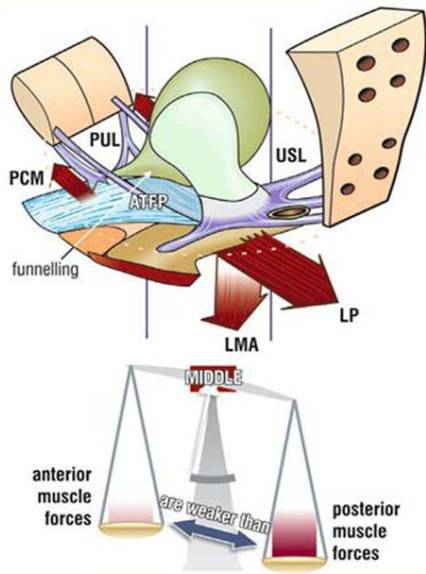


# CƠ CHẾ ĐI TIỂU

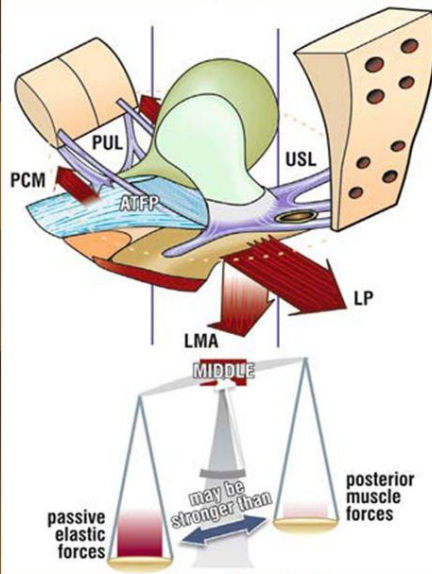


ACTIVE CLOSED

MICTURITION

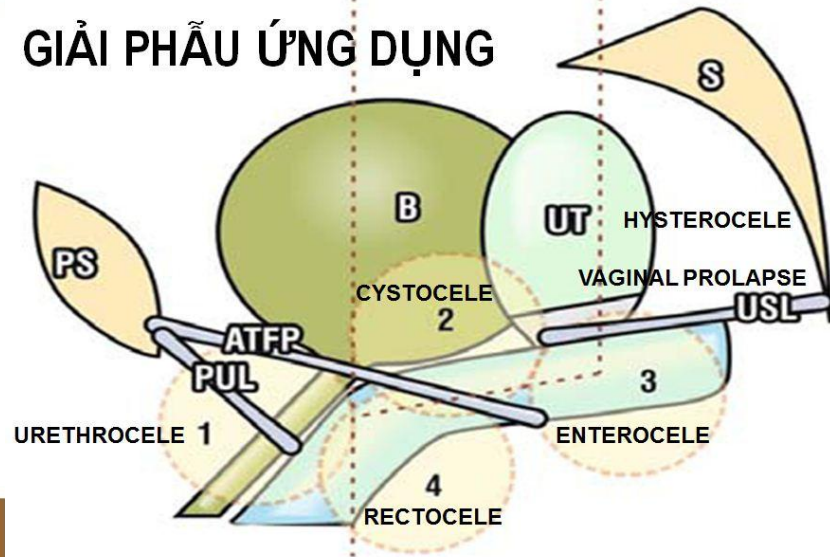


STRESS INCONTINENCE



ABNORMAL BLADDER EMPTYING<sup>31</sup>

## GIẢI PHẪU ỨNG DỤNG





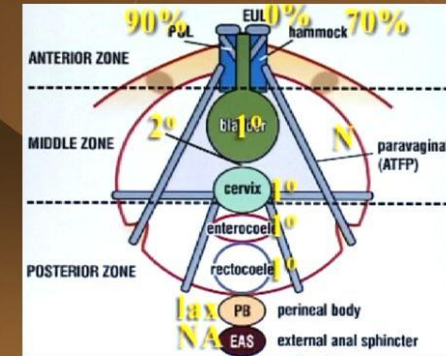
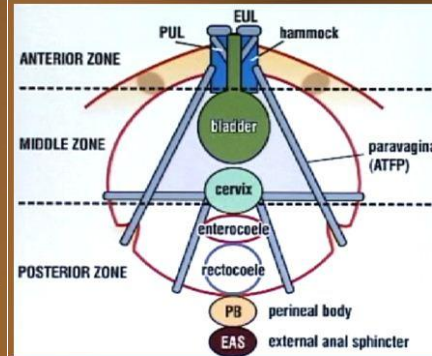
# CLINICAL DIAGNOSIS

ANTERIOR	MIDDLE	POSTERIOR
<b>Urethrocele</b> <b>PUL Hammock EUL</b> <b>stress incontinence</b> "unconscious" urine loss, ISD, cough-activated DI	<b>Cystocele</b> Para-vaginal defect <b>PCF ATFP</b>	<b>Enterocoele</b> Uterine prolapse Vaginal vault prolapse <b>USL RVF PB</b>
	<b>abnormal emptying</b> slow flow, hesitancy, "detrusor acontractility", "dyssynergia", overflow, dribble incontinence	
<b>frequency and urgency</b> sensory urgency, urge incontinence, low compliance bladder, urethra instability, detrusor instability, low bladder capacity		
		<b>nocturia</b>

33


# ZONES OF DAMAGE

Site specific pelvic examinations  
 → Exact location of pelvic floor weakness




34

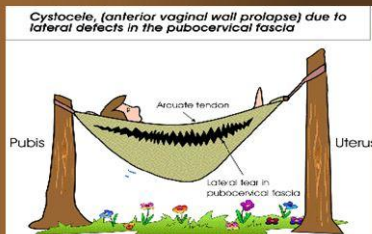
## URETHROCELE




## CYSTOCELE & UTERINE PROLAPSE



## CYSTOCELE



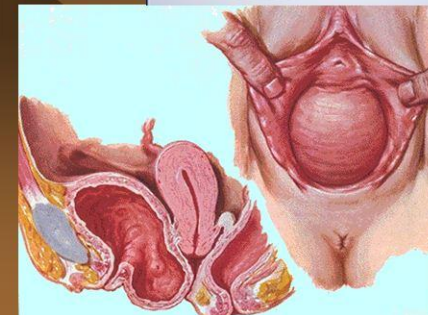
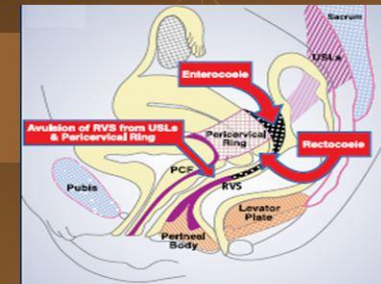
## UTERINE OR VAULT PROLAPSE



35

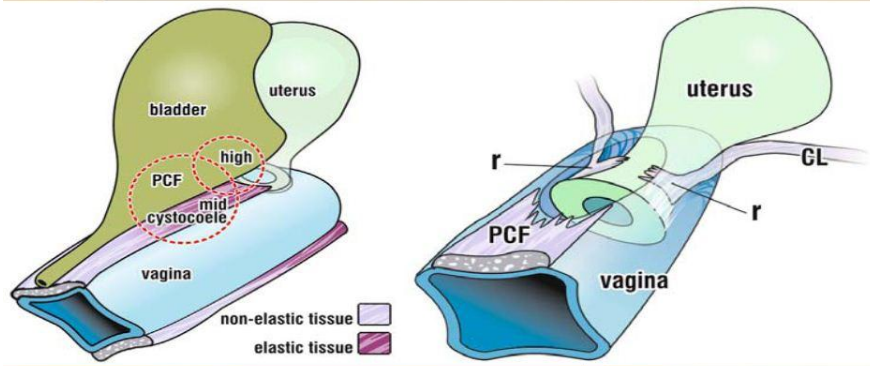
## TYPES OF GENITAL PROLAPSE

- ◆ Urethrocele
- ◆ Cystocele
- ◆ Vaginal vault prolapse
- ◆ Uterine prolapse
- ◆ Enterocoele
- ◆ Rectocele

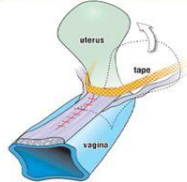


36

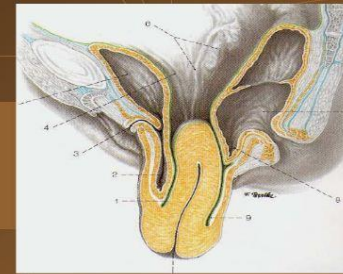
# Pubocervical fascia (PCF) → CYSTOCELE



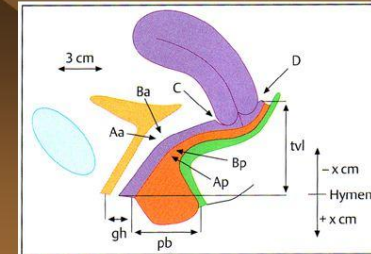
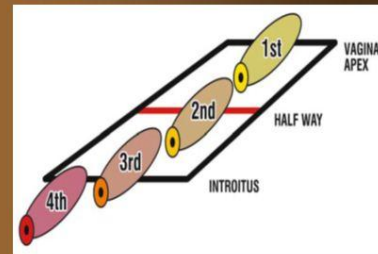
- A cystocele may be due to detachment of the trampolinelike pubovesicle septum from the proximal attachment to the **pericervical ring**, from the lateral attachments to the **white line**, or from its distal attachment to the **pubic ramus**. It can also result from a **central tear** in the septal fascia itself. Each and every defect must be evaluated and repaired to provide a long-term successful result.



# GENITAL PROLAPSE

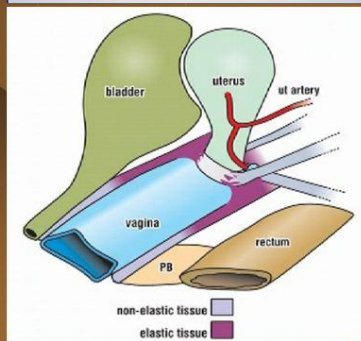
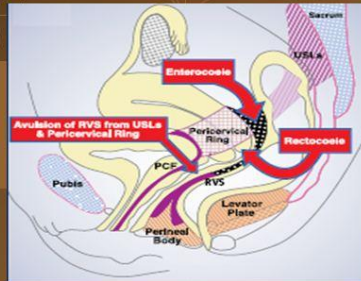


- Current grading systems → Degree of Genital prolapse  
**Baden-Walker (half way)**      **POP-Q**



## Supero-Posterior Fascial Axis:

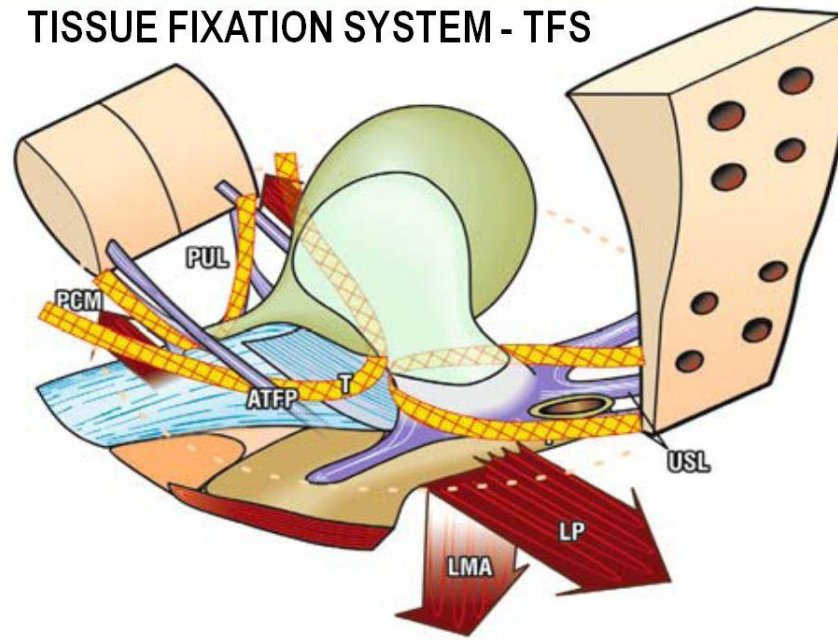
- Uterosacral ligaments (USL)
- Cardinal ligaments (CL)
- Cervical ring
- Rectovaginal fascia (RVF)
- Perineal Body (PB)



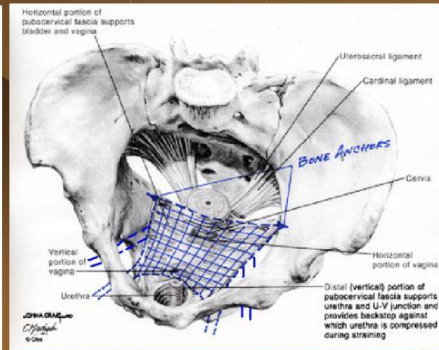
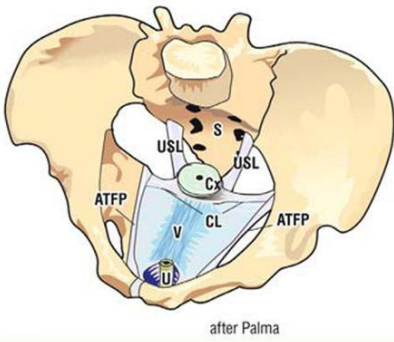
## Descending Perineum synd.

- Uterine descent
- Enterocoele
- Rectocoele

## TISSUE FIXATION SYSTEM - TFS

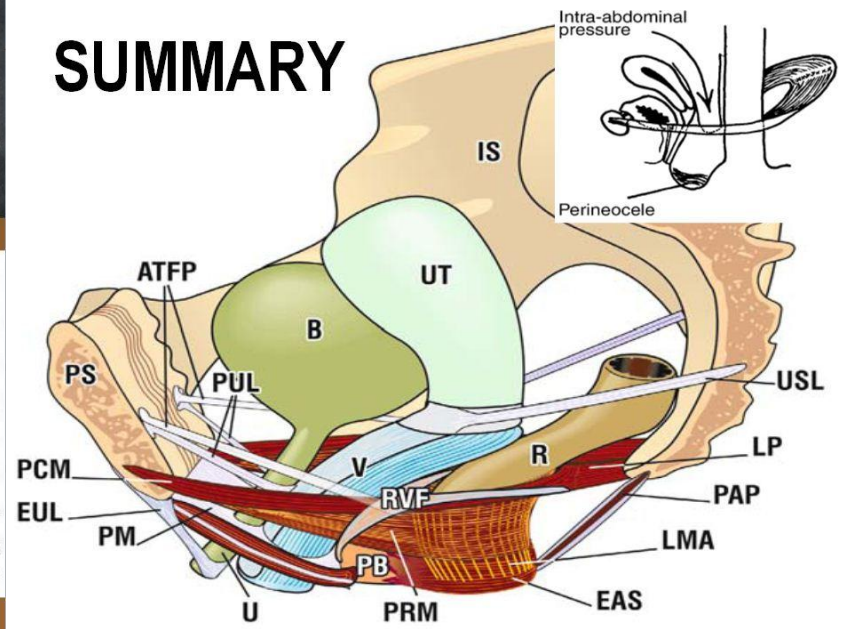


# INTRAVAGINAL POSTERIOR SLING - IVS



41

## SUMMARY



## THREE SUPPORT LEVELS

Level - I: Uterine Cervix

- Uterosacral ligament
- Cardinal ligament

(Tent pole)

Level - II: Horizontal Vagina

- Paracolpium, ATPF
- Pubocervical fascia
- Retrovaginal septum

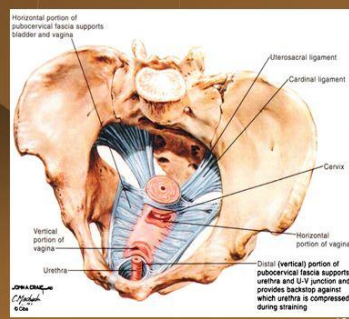
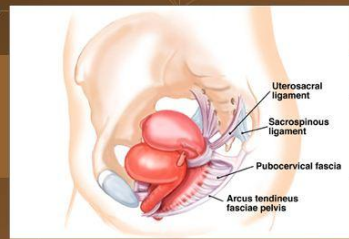
(Tent sides)

Level - III: Vertical Vagina

- Urethra & U-V Junction
- Perineal body (posterior)

(Tent pegs)

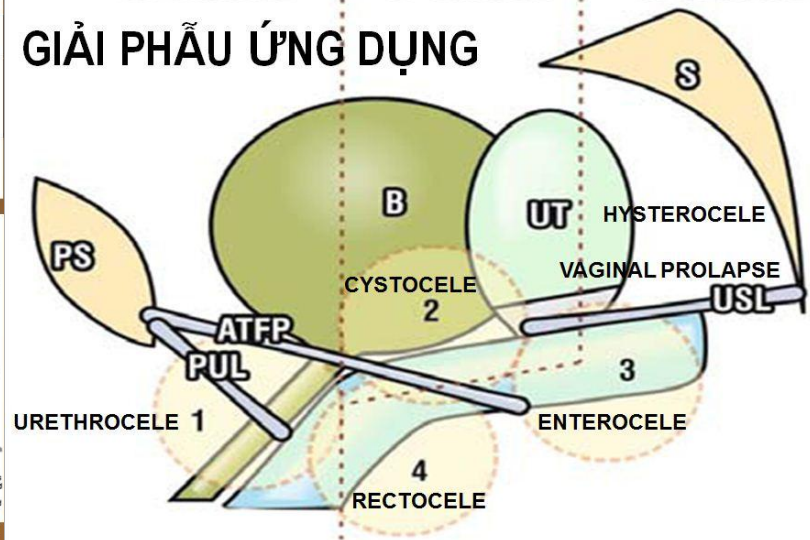
DeLancey JOL, Clinical Obstet and Gyecol (1993) 36: 4,897-909




43

ANTERIOR ZONE OF DAMAGE | MIDDLE ZONE OF DAMAGE | POSTERIOR ZONE OF DAMAGE

## GIẢI PHẪU ỨNG DỤNG



CẢM ƠN



ĐÃ LẮNG NGHE !

45

## TYPES OF GENITAL PROLAPSE

- ◆ Urethrocele
- ◆ Cystocele
- ◆ Vaginal vault prolapse
- ◆ Uterine prolapse
- ◆ Enterocele
- ◆ Rectocele

